

# **Hyperbaric Medicine Contraindications and Risk Factors**

---

**D. Lindsie Cone, MD, UHM, FUHM**

# Hyperbaric Medicine

## Contraindications

---

*Primary Training Course*

1

# Hyperbaric Medicine

## ...Contraindications

### What is the Evidence?

- Many contraindications in the past were based on anecdotal cases with very little evidence available.
- Some degree of “inherited ignorance” remains today.
- There remains a lack of information regarding some co-morbidities, medications and implantable devices

2

# Hyperbaric Medicine

## ...Contraindications

### Relative and Absolute

- Few absolute contraindications exists.
- A number of relative contraindications must be considered within the context of the clinical situation:
  - Emergent indications
  - Patient co-morbidities
  - Anticipated clinical outcome
  - Capabilities of the hyperbaric unit and staff

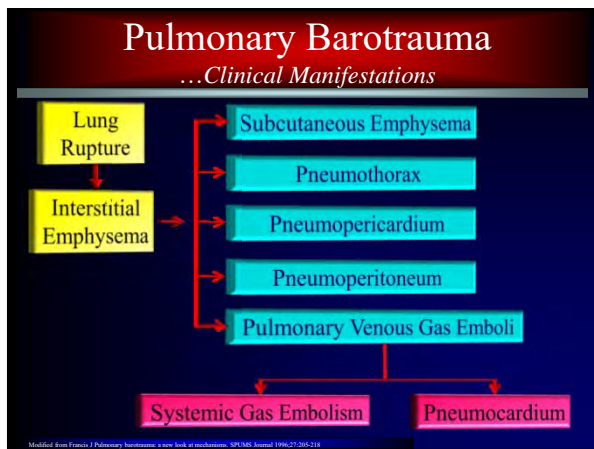
3

# Pulmonary Barotrauma

## ...Pathophysiology

- Alveolar membrane rupture typically results in interstitial emphysema and intrapulmonary bleb formation.
- Development of subpleural blebs may ultimately rupture resulting in pneumothorax and/or arterial gas embolism.

4



5

# Pulmonary Barotrauma

## ...Pathophysiology

### Autopsy and experimental data

- A positive relationship exists between adhesions, pleural damage, and pneumothorax.
- A negative relationship exists between parenchymal damage and fixed structures such as scars.

Calkins DE. Autopsy and experimental observations on factors leading to barotrauma in man. Undersea Biomedical Research 1985;12:165-182.

6

## Pulmonary Barotrauma

...Hooke's Elastic Law

---

*Ut tensio, sic vis*  
"As the extension, so the force"

---

- Lung tissue over a large volume will obey Hooke's Law.
- The stress (transmural pressure) imposed on the lung is directly proportional to the strain (increased volume) produced within the elastic limits.

7

## Pulmonary Barotrauma

...Pressure – Volume Relationship

---

8

## Pulmonary Barotrauma

...Pathophysiology

---

*Increased transtracheal pressure accompanied by increased volume*

---

“...the degree of overpressure required to cause tissue injury is dependent on the extent to which the lung is splinted by its surrounding structures.”

» T. J. R. Francis

The Lung of Depth, eds. Lindgren CGG and Miller DC, 1999, 112-111.

9

## Cerebral Arterial Gas Embolism

...Pathophysiology

---

*Large transtracheal pressures are tolerated when the chest and abdomen are bound - Calder, 1985*

---

- Alveolar membrane failure did not occur despite the presents of adhesions and transpulmonary pressures in excess of 200mmHg.
- Damage confined to interstitial emphysema
- Implication for anesthetized, sedated, or paralyzed patients.

10

## Pulmonary Barotrauma

...Pathophysiology

---

- Gas embolism is more frequently encountered in association with diving activities.
- Gas embolism appears to be rare in pulmonary barotrauma resulting from mechanical ventilation, exposure to altitude, or in the setting of spontaneous pneumothorax.

Mason R, Saly B. Diving and the lung. SPM 1985; 109:217-219.

11

## Absolute Contraindications

...Pulmonary Conditions

---

*Untreated Pneumothorax*

---

- Boyle's Law  
*Volume and pressure are inversely proportional*
- Trapped gas may lead to a tension pneumothorax
- Tube thoracostomy must be performed prior to treatment.
- Heimlich valve vs. pleurovac

12

## Absolute Contraindications

...Pulmonary Conditions

---

### Untreated Pneumothorax

---

- SETT trainee treated for CAGE with clinical 70% right pneumothorax and a 30% left pneumothorax. He was successfully treated initially on a USN table 6A and later converted to oxygen breathing at 60 fsw.

Broome JR and Smith DJ. Pneumothorax as a complication of recompression therapy for cerebral arterial gas embolism. *Crit Care Medical Research*, 1992;19: 447-455.

13

## Pulmonary Barotrauma

...In the Treatment of CAGE

---

### Bilateral pneumothoraces

---

- The patient was successfully decompressed to surface pressure without clinical compromise and without decompression of the thoraces.

Broome JR and Smith DJ. Pneumothorax as a complication of recompression therapy for cerebral arterial gas embolism. *Crit Care Medical Research*, 1992;19: 447-455.

14

## Pulmonary Barotrauma

...In the Treatment of CAGE

---

### Bilateral pneumothoraces

---

“Subsequent analysis of similar accidents suggests that pneumothorax need not cause major modifications to therapeutic decompression profiles, particularly if cases are treated on oxygen-based tables...”

- Broome

Broome JR and Smith DJ. Pneumothorax as a complication of recompression therapy for cerebral arterial gas embolism. *Crit Care Medical Research*, 1992;19: 447-455.

15

## Absolute Contraindications

...Pulmonary Conditions

---

### Untreated Pneumothorax

---

- Severe intoxication with COHbg  $\geq 50\%$ .
- All patients with episode of cardiac arrest and subsequent CPR prior to HBO.
- One patient with significant untreated wheezing before HBO.
- One patient with rib fracture.

Murphy DG, Sloan EP, Hart RG, et al. Tension pneumothorax associated with hyperbaric oxygen therapy. *Am J Emerg Med*, 1991;9:176-9.

16

## Pulmonary Barotrauma

...In the Treatment of CO Poisoning

---

### 3 cases of pneumothorax over 10 years

---

- All patients were successfully decompressed to ambient pressures without prior thoracentesis.
- Tension pneumothoraces definitively treated after leaving the chamber.
- All patients ultimately declared brain dead.

Murphy DG, Sloan EP, Hart RG, et al. Tension pneumothorax associated with hyperbaric oxygen therapy. *Am J Emerg Med*, 1991;9:176-9.

17

## Absolute Contraindications


...Pulmonary Conditions

---

### Untreated Pneumothorax

---

- 297 consecutive cases of CO poisoning
- 1% risk of tension pneumothorax (3 cases)
- 12% risk if – comatose, intubated and received CPR (N=23)



Murphy et al. *AJEM* 1991;9(2): 176-170

18

## Pulmonary Barotrauma

...Hyperbaric Oxygen for Flap Salvage

### Tension pneumothorax

- 55 y/o female treated in a multiplace chamber for pedicle flap salvage to the floor of the mouth.
- Decompression profile with maximum pressure change of 2.4 psi/min.
- Patient became symptomatic, was recompressed and successfully decompressed to ambient pressure at 1 foot/min (0.445psi/min).

Liswath D. Case report: Pulmonary barotrauma in a hyperbaric chamber. *Anaesthesia*. 1993 Nov;26(11):475-8.

19

## Hyperbaric Medicine

... Absolute contraindications

### Spontaneous Pneumothorax

- Patients who have experienced a spontaneous pneumothorax are at risk for recurrences.
  - Particularly true within the succeeding 12 months
  - Patients who have not undergone pleurodesis

20

## Hyperbaric Medicine

... Absolute contraindications

### Traumatic Pneumothorax Recommendations

- Traumatic pneumothorax
  - Flight allowed 2 weeks after full radiographic resolution
- Thoracic surgery
  - Air travel should be delayed for at least 2 weeks after uncomplicated surgery.
  - CXR confirmation of pneumothorax resolution
  - Careful medical assessment prior to flight

British Thoracic Society Standards of Care Committee: Air Travel Working Party. *Thorax*. 2011;66(1):e30

21

## Hyperbaric Medicine

... Absolute contraindications

### Bronchogenic Cyst

- 40 y/o non-smoking female without h/o pulmonary, neurologic, or cardiac history developed acute severe chest pain followed by loss of consciousness 10 minutes after takeoff.
- A clinical diagnosis of CAGE was made.

Air Embolism during an Aerial Flight in a Passenger with a Pulmonary Cyst: A Favorable Outcome with Hyperbaric Therapy. *Anesthesiology*. Volume 161, Issue 2 (August 2004)


22

## Hyperbaric Medicine

... Absolute contraindications

### Bronchogenic Cyst

- Chest radiograph and CT of the chest revealed a large thin-walled cyst.
- No evidence of extrapleural air.



Air Embolism during an Aerial Flight in a Passenger with a Pulmonary Cyst: A Favorable Outcome with Hyperbaric Therapy. *Anesthesiology*. Volume 161, Issue 2 (August 2004)

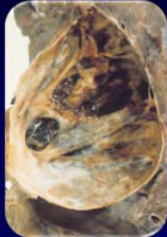
23

## Hyperbaric Medicine

... Absolute contraindications

### Bronchogenic Cyst

- The patient expired with autopsy findings c/w multiple cerebral and myocardial infarctions.



Air Embolism during an Aerial Flight in a Passenger with a Pulmonary Cyst: A Favorable Outcome with Hyperbaric Therapy. *Anesthesiology*. Volume 161, Issue 2 (August 2004)

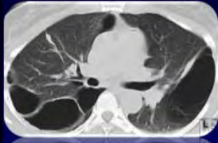
24

## Hyperbaric Medicine

...Absolute contraindications

### Large Pulmonary Blebs

- Higher incidence of CAGE
- Consider patients with long time constants.
- Consider risk/benefit and expected outcomes.




25

## Hyperbaric Medicine

...Absolute contraindications

### Large Pulmonary Blebs

- Utilize slow decompression rates (0.45 psi/min).
- Provide in-chamber bronchodilator nebulizer as appropriate.
- Consider prophylactic chest tube(s).



26

## Hyperbaric Medicine

... Relative contraindications

### Spontaneous Pneumothorax Recommendations

- Previous pneumothorax
  - Treated with thoracotomy and surgical pleurodesis / talc insufflation, then no subsequent travel restriction
  - Non-talc pleurodesis associated with a continued risk of recurrence
  - With no definitive procedure, recurrence is expected and air travel is not recommended

British Thoracic Society Standards of Care Committee Air Travel Working Party. Thorax. 2011;66(1):30

27

## Hyperbaric Medicine

...Relative contraindications

### Obstructive Lung Disease

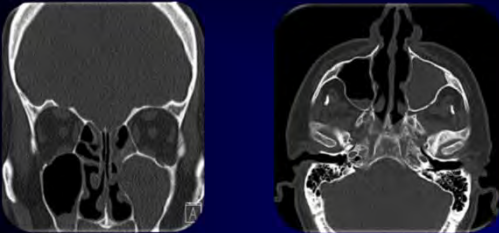
- Barotrauma/air trapping
- Carbon dioxide retention
- Loss of hypoxia drive
- Prophylaxis with B<sub>2</sub> agonist aerosols
- Slow ascent rates (1 psi/min)

28

## Hyperbaric Medicine

... Relative contraindications

### Upper Respiratory Tract Infection



Maxillary sinus squeeze with hemorrhage

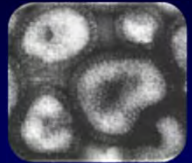
29

## Hyperbaric Medicine

... Relative contraindications

### Acute Viral Infection

- HBO without antiviral effects
- Increased risk of barotrauma
- Decongestants etc. for emergent indications
- Delay elective indications




30

## Hyperbaric Medicine

... Relative contraindications

### HIV and HBO

- Hypoxia slows viral replication
- No controlled studies
- No effect on CD count (Myers 93)
- Improved HIV related fatigue (Myers 93)



31

## Hyperbaric Medicine

... Relative contraindications

### HIV and HBO

- Pentamidine increases bleb formation
- More than one episode of PCP pneumonia impart 10 fold increased risk of bleb formation

32

## Hyperbaric Medicine

... Relative contraindications

### Diabetes Mellitus (Hypoglycemia)

- A patient with type II diabetes mellitus who initially required insulin or oral hypoglycemic drugs for glucose control.
- After significant weight loss the patient no longer required medication and now has a HbgA1c within the normal range.
- Does this patient remain at risk for HBO induced hypoglycemia?

33

## Hyperbaric Medicine

... Relative contraindications

### Diabetes Mellitus (Hypoglycemia)

- The diabetic patient is well known to be at risk for developing hypoglycemia under hyperbaric hyperoxic conditions.
- Patients whose glucose homeostasis is restored, as evidenced by 1) no longer requiring medications, 2) normal fasting BS, 3) normal postprandial BS, and 4) normal glycosylated hemoglobin values, should no longer be at risk of HBO induced hypoglycemia.

34

## Hyperbaric Medicine

... Relative contraindications

### Diabetes Mellitus

- New onset type II diabetics may exhibit a “honeymoon” period where their blood sugars are initially well controlled.
- Pancreatic transplant patients may not achieve return of autonomous glycemic control and counter regulatory hormone function.
- Initial pre and post HBO treatment BS analysis may be considered.

35

## Hyperbaric Medicine

... Relative contraindications

### Hyperthyroidism

Should I be concerned about a patient referred for hyperbaric oxygen therapy who has hyperthyroidism?

36

## Hyperbaric Medicine

... *Relative contraindications*

### Hyperthyroidism

- Hyperthyroidism increases the susceptibility of tissues to elevated oxygen pressures (Bean and Johnson - 1955).
- Consider lower treatment pressures and/or institution of air breaks as appropriate.
- Be mindful of the increased risk to pulmonary toxicity in the critically ill who require high baseline  $F_iO_2$ .

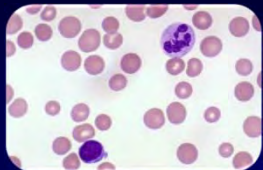
37

## Hyperbaric Medicine

... *Relative contraindications*

### Hereditary Spherocytosis

- Autosomal dominant with variable penetrance
- Normal MCV
- +/- Anemia
- Increased reticulocyte count



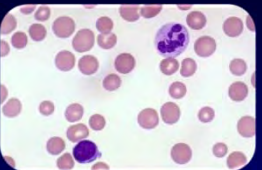
38

## Hyperbaric Medicine

... *Relative contraindications*

### Hereditary Spherocytosis

- Increased hemolysis
- Increased osmotic lysis
- Monitor CBC and reticulocyte count
- 400 IU of Vitamin E



39

## Hyperbaric Medicine

... *Relative contraindications*

### Sickle Cell Anemia

- 1 in 500 Black Americans
- 1 in 1000 Hispanic Americans
- Inflexible, odd shaped, fragile cells increase blood viscosity, stasis, and mechanical obstruction.
- May result in vaso-occlusive crisis (Pain Crisis), aplastic crisis, or hyperhemolytic crisis.




40

## Hyperbaric Medicine

... *Relative contraindications*

### Sickle Cell Anemia

- Pain Crisis Study (Unpublished)
  - Sickle cell priapism
  - Increased seizures compared to control
- Increased circulating epinephrine during a pain crisis likely contributes to increased CNS oxygen toxicity.
- Defer elective HBO during pain crisis.
- HBO safely used when not in crisis.
- Anecdotally - HBO helpful in appropriate sickle cell related ulcers.



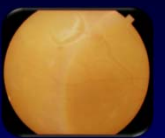
41

## Hyperbaric Medicine

... *Relative contraindications*

### Retinal Detachment with Gas Tamponade

- A 54 y/o male diabetic developed scotomata in the right eye.
- Diagnosed with an retinal detachment with background diabetic retinopathy.
- Was being seen in the wound center with a left plantar heel wound with chronic osteomyelitis.
- Surgical debridement planned with HBO to be started post op.



42

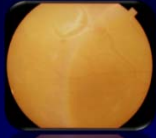


## Hyperbaric Medicine

... Relative contraindications

### Retinal Detachment with Gas Tamponade

- Intraocular gas tamponade with Sulfur Hexafluoride (SF<sub>6</sub>) was scheduled by ophthalmology.
- Can this patient safely undergo hyperbaric oxygen therapy?




43

## Hyperbaric Medicine

... Relative contraindications

### Retinal Detachment with Gas Tamponade

- Retinal detachment can be successfully treated with instillation of intraocular gas which serves to hold the retina in place.
- Gases typically used include Sulfur Hexafluoride (SF<sub>6</sub>) and Perfluoropropane (C<sub>3</sub>F<sub>8</sub>).




44

## Hyperbaric Medicine

... Relative contraindications

### Characteristics of Intraocular Gases

- Intraocular gas undergoes 3 phases:
  - Expansion
  - Equilibrium
  - Dissolution



Gas	MW	Max Expansion (hrs.)	Duration	Non-expansile concentration	Expansivity
Air	29	N/A	5-7 days	N/A	0
SF <sub>6</sub>	146	24-48	1-2 weeks	20%	2
C <sub>2</sub> F <sub>6</sub>	138	36-60	4-5 weeks	16%	3.3
C <sub>3</sub> F <sub>8</sub>	188	72-96	6-8 weeks	12%	4

45

## Hyperbaric Medicine

... Relative contraindications

### HBO and Intraocular Gas

- Will result in hypotony and globe collapse under pressure – Boyle's Law.
- Oxygen diffusion into the bubble may lead to increased intraocular pressure on decompression – 35% increase in volume during normobaric oxygen ventilation.
- Prolonged contact of intraocular gas with the posterior lens can lead to cataract formation.

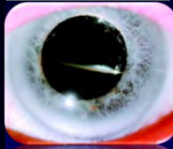
46

## Hyperbaric Medicine

... Relative contraindications

### Recommendations

- Intraocular gas volume is difficult to estimate.
- HBO should be held until intraocular gas is resorbed if possible.
- Alternative use of silicone oil for tamponade.
- Informed consent should cover cataract formation.



Jickman SV, Thompson JT. Effects of hyperbaric exposure on eyes with intraocular gas bubbles. *Retina*. 1995;15:160-6.

47

## Hyperbaric Medicine

... Relative contraindications

### Congestive Heart Failure

- Patient with CHF (EF 30%) who completed 22 HBO treatments without difficulty – 2.4 ATA x 90 min.
- On the 23<sup>rd</sup> treatment she developed dyspnea and became diaphoretic and was ultimately diagnosed with a CHF exacerbation.
- After cardiac clearance, what other precautions should be taken? Should the treatment pressure be lowered. Should air breaks be provided?

48

## Hyperbaric Medicine

... Relative contraindications

### Congestive Heart Failure

- Exacerbation of CHF is a known but, relatively uncommon complication of HBO.
- Typically, patients will become symptomatic in the latter stages of a 90 minutes treatment.
- Many will do well with decompression while others may require diuretics or critical care.
- Compromise under pressure is not well correlated with ejection fraction.

49

## Hyperbaric Medicine

... Relative contraindications

### Congestive Heart Failure

- Underlying mechanism of worsening heart failure in the hyperbaric setting is not entirely clear.
- One possible mechanism is that of ventricular imbalance.
- In the setting of systolic dysfunction cardiac output is afterload dependent.
- Oxygen dependent peripheral vasoconstriction results in an increase in left ventricular afterload.

50

## Hyperbaric Medicine

... Relative contraindications

### Congestive Heart Failure

- Oxygen dependent pulmonary vasodilation results in a decrease in RV afterload.
- A decrease in left heart output relative to the right of only 2% can result in an additional liter of fluid in the pulmonary vascular bed over a 10 minute period of time.
- The degree of compromise would be dependent on the oxygen dose.

51

## Hyperbaric Medicine

... Relative contraindications

### Congestive Heart Failure Recommendations

- All CHF patients should be maximally medically managed and well compensated prior to a trial of pressure if the clinical condition allows.
- Blood pressure should be adequately controlled.
- Lower treatment pressures will potentially lessen the increase in left ventricular afterload.
- Theoretically, air breaks may be of benefit in reducing the oxygen induced vasoconstriction and resulting increased afterload.
- Anxiety associated with HBO treatments should be adequately addressed.


52

## Hyperbaric Medicine

... Relative contraindications

### Optic Neuritis

- 25% incidence in Multiple Sclerosis.
- Primary inflammation of the optic disc.
- Most commonly acute demyelinating optic neuritis.
- Optic disc may be spared resulting in retrobulbar optic neuritis.
- Optic disc may be swollen resulting in papillitis.



53

## Hyperbaric Medicine

... Relative contraindications

### Optic Neuritis

Adults - Usually unilateral

- 38% develop MS within 10 years
- 50% will ultimately develop MS

Children - Usually bilateral

- Papillitis more common
- Severe vision loss more common
- 13% develop MS within 10 years
- 19% develop MS within 20 years

54

## Hyperbaric Medicine

... Relative contraindications

### Optic Neuritis

- History of Optic neuritis is a relative contraindication
- Active Optic neuritis should delay HBO except in life-threatening indications.
- Active Optic Neuritis requires ophthalmology consult
- Optic neuritis is associated with MS
- MS is not an approved indication for HBO

55

## Hyperbaric Medicine

... Relative contraindications

### Hyperthermia

- Decreased central oxygen tolerance
- Treat the underlying cause
- Administer antipyretics
- Seizure prophylaxis with anticonvulsants or “air breaks” with temperature  $\geq 100^{\circ}\text{F}$

56

## Hyperbaric Medicine

... Relative contraindications

### Claustrophobia

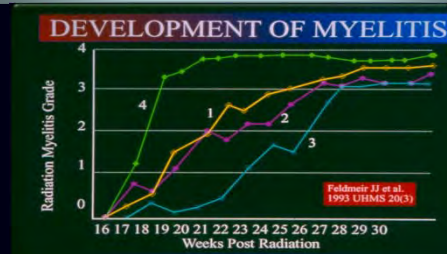- True claustrophobia is a relatively uncommon occurrence.
- Have patient visit chamber prior to treatment
- Have the patient preview a treatment
- Have a responsive attentive staff
- Benzodiazepines

57

## Hyperbaric Medicine

... Relative contraindications

### Concurrent Spinal Cord Radiation



58

## Hyperbaric Medicine

... Relative contraindications

### Concurrent Spinal Cord Radiation

- “Patients receiving therapeutic irradiation should probably avoid concurrent HBO therapy if the spinal cord is encompassed within the radiation treatment volume.”

Feldmeir JJ, et al. Hyperbaric oxygen as prophylaxis or treatment for radiation myelitis. *UHM* 1993; 20:249-255.

59

## Hyperbaric Medicine

... Relative contraindications

### Amiodarone Pneumonitis

- Iodinated benzofuran effective in the treatment of ventricular and supraventricular tachyarrhythmias.
- Amiodarone pulmonary toxicity (APT), “amiodarone lung”, was first described in the early 1980’s
- May develop within a few months to several years with a cumulative prevalence of 1-15%

60

## Hyperbaric Medicine

... *Relative contraindications*

### Amiodarone Pneumonitis

- Signs and symptoms are non-specific
- Characterized by progressive dyspnea over several weeks
- Associated with a precipitous decrease in diffusing capacity ( $D_LCO$ ).
- Diagnosis is by exclusion in the absence of lung biopsy.

61

## Hyperbaric Medicine

... *Relative contraindications*

### Amiodarone Pneumonitis

- May manifest clinically as
  - Solitary lung mass
  - Chronic interstitial pneumonitis
  - Organizing pneumonia with or without bronchiolitis obliterans (BOOP)
  - Acute respiratory distress syndrome

62

## Hyperbaric Medicine

... *Relative contraindications*

### Amiodarone Pneumonitis Pathogenesis

- Incompletely understood.
- Parent drug and metabolite(s) directly toxic to lung cells – lung concentrations 100-500 fold serum levels.
- Indirect immunological reaction – inflammation
- Reactive oxygen species directed lung injury

63

## Hyperbaric Medicine

... *Relative contraindications*

### Amiodarone Pneumonitis Pathogenesis

- Exposure to increased concentrations of inspired oxygen has been implicated in the development of APT.
- Mechanical ventilation may have synergistic effects with high  $F_iO_2$ .

64

## Hyperbaric Medicine

... *Relative contraindications*

### Amiodarone Recommendations

- Risk/benefit of HBO must be assessed in patients taking amiodarone.
- Increased risk in the critically ill, post surgical patients, and those on high daily drug doses.
- Patients should be closely monitored utilizing PFTs with diffusion capacity.
- Decreased  $D_LCO > 15\%$  highly sensitive;  $> 30\%$  highly specific
- Be aware of hyperthyroidism and oxygen toxicity

65

## Hyperbaric Medicine

... *Relative contraindications*

### Active Malignancy

- Theoretical and historical concern related to tumor angiogenesis
- HBO upregulates VEGF which is often targeted in metastatic cancers.
- Can HBO enhance tumor angiogenesis
- Must consider all options and weigh the risks and potential benefits.

66

## Hyperbaric Medicine

... Relative contraindications

### Active Malignancy

- Theoretical and historical concern related to tumor angiogenesis
- HBO upregulates VEGF which is often targeted in metastatic cancers.
- Can HBO enhance tumor angiogenesis
- Must consider all options and weigh the risks and potential benefits.

67

## Hyperbaric Medicine

... Relative contraindications

### Avastin®

- Avastin® (Bevacizumab) – utilized in the treatment of metastatic disease
- Recombinant humanized monoclonal IgG1 antibody that binds to Vascular Endothelial Growth Factor (VEGF)
- Inhibits the interaction of VEGF with receptors on the endothelial cell surface.
- Effectively prevents the proliferation of endothelial cells and formation of new blood vessels.

68

## Hyperbaric Medicine

... Relative contraindications

### Avastin®

- Avastin® (Bevacizumab) – utilized in the treatment of metastatic disease
- Recombinant humanized monoclonal IgG1 antibody that binds to Vascular Endothelial Growth Factor (VEGF)
- Inhibits the interaction of VEGF with receptors on the endothelial cell surface.
- Effectively prevents the proliferation of endothelial cells and formation of new blood vessels.

69

## Hyperbaric Medicine

... Relative contraindications

### Avastin® Boxed Warnings

- The incidence of wound healing and surgical complications is increased in Avastin-treated patients.
- Do not initiate Avastin for at least 28 days after surgery and until the surgical wound is fully healed.
- The appropriate interval between termination of Avastin and subsequent elective surgery required to reduce the risks of impaired wound healing/wound dehiscence has not been determined.

Genentech

70

## Hyperbaric Medicine

... Relative contraindications

### Avastin® and Angiogenesis

- The effects of hyperbaric oxygen on wound healing may be significantly diminished with concomitant use of Avastin.
- The appropriate interval between termination of Avastin and subsequent elective surgery required to reduce the risks of impaired wound healing/wound dehiscence has not been determined.
- At the present time Avastin therapy does not constitute a contraindication for HBO.

71

## Hyperbaric Medicine

... Relative contraindications

### Cis Platinum

- Interferes with DNA synthesis
- Delays fibroblast proliferation
- Delays collagen synthesis
- Delays wound healing when used w/HBO
- Decreases wound breaking strength in mice

• Nemiroff 1988

72

## Hyperbaric Medicine

... Relative contraindications

### Doxorubicin

- Inhibits DNA synthesis
- Promotes free radical formation
- Upton found 87% mortality in rats given HBO/Doxorubicin within 4 weeks.
- Presumably due to free radical induced cardiac toxicity

Upton et al. 1986 *Cancer Treatment Reports*, 70, 503-507.

73

## Hyperbaric Medicine

... Relative contraindications

### Doxorubicin

- Wistar rats treated with HBO, Doxorubicin or both studied for 8 weeks with Echocardiography then sacrificed and studied histologically
- Doxorubicin significantly reduced EF ( $p < 0.001$ ) and caused severe injury based on histology ( $p < 0.05$ )
- HBO plus Doxorubicin also reduced EF ( $p < 0.001$ ) but reduction was significantly less than with Doxorubicin alone ( $p < 0.05$ ).
- HBO / Doxorubicin combination attenuated the histopathological injury ( $p < 0.05$ ).

Karagoz et al. 2007 *Nordic Pharmacological society Basic & Clinical Pharmacology & Toxicology*, 102, 287-292

74

## Hyperbaric Medicine

... Relative contraindications

### Doxorubicin

- “Cardioprotection conferred with HBO<sub>2</sub> against doxorubicin warrants further investigation”
- Wait one week before beginning therapy (87 hours = 5 half-lives)?

75

## Hyperbaric Medicine

... Relative contraindications

### Bleomycin

- Bleomycin results in DNA strand scission secondary to generation of reactive oxygen species
- Acute pulmonary toxicity may occur in up to 40% of patients with a fatality rate of 1.5%.
- Acute toxicity is attributed to a dose-dependent hypersensitivity reaction.

76

## Hyperbaric Medicine

... Relative contraindications

### Bleomycin

- Delayed reactions may occur up to 6 months.
- Supplemental oxygen after bleomycin therapy has been reported to result in severe and potentially fatal pulmonary complications.
- Bleomycin remained an absolute contraindication to HBO as late as 2008.

77

## Hyperbaric Medicine

... Relative contraindications

### Bleomycin

- Pulmonary fibrosis may occur in 10% of patients.
- Restrictive pattern on PFTs
- Decreased diffusion capacity (DLCO)

78

## Hyperbaric Medicine

*... Relative contraindications*

### Bleomycin

- Evaluate each patient appropriately.
- Wait 3-6 month post bleomycin therapy prior to HBO.
- Establish baseline pulmonary function with spirometry, DLCO, and appropriate imaging.
- Monitor for adverse changes during HBO

Klaus DT, et. Al. Safe administration of hyperbaric oxygen after bleomycin: a case series of 15 patients. *UHM* 2012;39:873-879

79

## Hyperbaric Medicine

*... Relative contraindications*

### Sulfamylon

- A carbonic anhydrase inhibitor which produces a metabolic acidosis thus increasing the risk of oxygen toxicity seizure
- Associated with increased mortality in animals (Burnside 1968)
- Silvadene is an acceptable alternative

80

## Hyperbaric Medicine

*... Relative contraindications*

### Disulfiram

- Competes with enzymes containing SH bonds for free radical oxygen molecules thus protective
- Blocks the production of Superoxide Dismutase which protects the body against oxygen toxicity
- A single HBO exposure is acceptable, but repetitive HBO txs. unacceptably increases the patient's risk.

81

## Hyperbaric Medicine

*... Case Presentation*

### To treat or not to treat

- Pt. with h/o ORN of the mandible
- S/p free fibular flap, removal of previous hardware and partial mandibulectomy
- Complex closure with STSG to neck.
- Sustained a left apical pneumothorax with placement with placement of a feeding tube
- Tube thoracostomy was performed.

82

## Hyperbaric Medicine

*... to treat or not to treat*

### Case Presentation

- On post-operative day 1 a CXR was consistent with a LLL pneumonia and right pleural effusion.
- He is currently a week out now from surgery and the jaws are wired shut for a minimum of 6 weeks postoperatively.
- Conservatively speaking in the HBO outpatient world .... what should be a safe time to return to treatment?

83

## Hyperbaric Medicine

*... Case Presentation*

### What are the issues?

- Pneumothorax
  - Treated or untreated?
  - Continued air leak?
- Pneumonia
  - Air trapping and risk for barotrauma?
- Jaws are wired closed
  - Aspiration risk
  - Airway compromise in a monoplace chamber.

84

## Hyperbaric Medicine

... Case Presentation

### What are the issues?

- Does the patient really need any further HBO therapy?
- Has pre-op HBO treatment to augment neovascularization been provided? If so, post op treatments may not be necessary.
- The free fibular composite graft was harvested outside the irradiated field
- Is the flap or the STSG compromised?

85

## Hyperbaric Medicine

... Case Presentation

### What are the answers?

- A *treated* pneumothorax is not an absolute contraindication for treatment nor is a LLL pneumonia; however, the risk vs. benefit must be examined closely prior to providing a trial of pressure.
- The chest tube must be properly managed
- The patient must be able to tolerate water seal if appropriate suction capability is not available.

86

## Hyperbaric Medicine

... Case Presentation

### What are the answers?

- Employ a slow decompression rate of 0.5psi/min to lessen the risk of pulmonary barotrauma.
- Keep the head elevated as much as possible.
- Wire cutters should be available
- Treat at 2 ATA to lessen the risk of a seizure.
- An air break could be considered

87

## Hyperbaric Medicine

...Contraindications

Thank You  
Questions?

88



# Hyperbaric Oxygen Contraindications

## Absolute

---

### Cardio-pulmonary:

1. Untreated pneumothorax
2. Bronchogenic cyst

## Relative

---

### Cardio-pulmonary:

1. Spontaneous pneumothorax
2. Obstructed lung disease
3. History of thoracic surgery/trauma
4. Pneumonia
5. Bullous emphysema
6. PCP pneumonia and current or previous Pentamidine tx
7. Congestive heart failure (decompensated)

### Endocrine:

1. Diabetes mellitus with relative hypoglycemia
2. Hyperthyroidism

### Hematologic:

1. Hereditary spherocytosis
2. Sickle cell vaso-occlusive crisis
3. G6PD deficiency
4. HIV disease

### Neuropsychiatric:

1. Seizure disorder (uncontrolled)
2. Elevated intracranial pressure
3. Confinement anxiety

### Medications:

1. Sulfamylon
2. Disulfiram
3. Corticosteroids
4. Sympathomimetic amines
5. High dose aspirin
6. High dose vitamin C
7. Narcotics
8. Cis Platinin
9. Doxorubicin
10. Bleomycin
11. Doxorubicin
12. Avastin

### Otolaryngological:

1. Upper respiratory tract infection
2. Otitis media
3. Otic barotrauma
4. History of ear reconstructive surgery

### Ophthalmic:

1. Intraocular gas
2. Cataracts
3. Optic neuritis

### Other:

1. Concurrent spinal radiation
2. Pregnancy
3. Hyperthermia

## References

1. Assali NS, et *al.*: **Effects of hyperbaric oxygen on uteroplacental and fetal circulation.** Circulation Res. 1968; 22:573-588.
2. Boveris A, et *al.*: **Synergism of hyperbaric oxygen and adriamycin.** 2nd European Conference on Hyperbaric Medicine 1989:61-64, Basil Switzerland.
3. Brown DB, et *al.*: **Hyperbaric oxygen treatment for carbon monoxide poisoning in pregnancy: A case report.** Aviation, Space, and Environmental Medicine 1992:1011-1014.
4. Cho SH, Yun DR: **The experimental study on the effect of the hyperoxygenation on the pregnancy wastage of the rats in acute carbon monoxide poisoning.** Seoul J. Med. 1982; 23:66-75.
5. Clark JM: **Oxygen Poisoning.** San Antonio Medical Seminars, Inc. 1981.
6. Clarke D: **Cancer as a risk factor.** Hyperbaric Medicine 1992, Columbia, South Carolina.
7. Davis JC, Dunn JM, Teimbach RD: **Hyperbaric Medicine: Patient selection, treatment procedures and side effects.** In: Davis JC, Hunt TK, eds. Problem Wounds: The Role of Oxygen. New York: Elsevier 1988:225-235.
8. Evans JC: Radiology 1969; 93:1155-1157.
9. Feder B, et *al.*: **The effect of hyperbaric oxygen on pulmonary metastases in C3H mice.** Radiology 1968;90(6):1181-1184.
10. Feldmeier JJ, et *al.*: **Hyperbaric Oxygen: Does it Promote Growth or Recurrence of Malignancy?** Undersea Hyperbaric Medicine 2003; 30(1):1-18.
11. Feldmeier JJ, et *al.*: **Do concerns that hyperbaric oxygen therapy may be carcinogenic impact on hyperbaric patterns: The results of a national survey.** UHMS Scientific Meeting 1992:107, Bethesda, Maryland.
12. Ferm VH: **Teratogenic effects of hyperbaric oxygen.** Proc. Soc. Exp. Biol. Med. 1964; 116:975-976.
13. Foster JH: **Hyperbaric oxygen therapy: Contraindications and Complications.** Journal of Oral and Maxillofacial Surgery 1992:1081-1086.
14. Fujikaro T: **Retrolental Fibroplasia and prematurity in new born rabbits induced by maternal hypoxia.** American Journal of Obstetrics and Gynecology 1964; 90:854-858.
15. Gilman SC, et *al.*: **Fetal development: Effects of decompression sickness and treatment.** Aviation, Space, and Environmental Medicine 1983; 54:1040-1042.
16. Granstrom G, et *al.*: **Hyperbaric oxygenation does not stimulate experimental tumor growth.** EUBS Proceedings: Joint Meeting on Diving and Hyperbaric Medicine 1990, Amsterdam, The Netherlands.
17. Jackman SV, Thompson JT: **Intraocular pressure response to simulated hyperbaric oxygen therapy in eyes with intraocular gas bubbles.** UHMS Annual Scientific Meeting 1992:109, Bethesda, Maryland.
18. Jennings RT: **Women and the hazardous environment: When the pregnant patient requires oxygen therapy.** Aviation, Space, and Environmental Medicine 1987:370-374.
19. Johnson R, et *al.*: **The effect of hyperbaric oxygen on tumor metastases in mice.** Clinical Radiology 1971; 22:538-540.
20. Kakhnovsky IM, et *al.*: **The mechanism of hypoglycemia effect of hyperbaric oxygenation in Diabetes Mellitus patients.** Proceedings of the VIII International Congress on Hyperbaric Medicine, Moscow 1981.
21. Kindwall EP, Goldmann RW eds: **Hyperbaric Medicine Procedures.** Milwaukee, Wisconsin 1988:1-3.
22. Kindwall EP: **Uses of hyperbaric oxygen therapy in the 1990's.** Cleveland Clinic Journal of Medicine 1992;59(5):517-528.
23. Lawrence WT, et *al.*: **The detrimental effect of cigarette smoking on flap survival: An experimental study in the rat.** British Journal of Plastic Surgery 1984; 37:216-219.
24. Lucey JF, Dangman B: **A re-examination of the role of oxygen in retrolental fibroplasia.** Pediatrics 1984; 73(1):82-96.
25. Lyne AL: **Ocular effects of hyperbaric oxygen.** Trans Ophthal Soc UK 1978; 98:199-201.
26. Mader JT: **Hyperbaric oxygen committee report.** Bethesda, Maryland 1989.
27. Marx R, et *al.*: In: Problem Wounds: The Role of Oxygen 1988; 4:107-110. Elsevier Science Publishing Co., New York.

28. Massaro D: **Oxygen: Toxicity and Tolerance.** Hospital Practice 1986; 4:95-101.
29. McCredie J, et *al.*: **Effects of hyperbaric oxygen on growth and metastases of the C3HBA tumor in the mouse.** Cancer 1966; 19:1537-1542.
30. McHugh T, Clarke D: **Introduction to Hyperbaric Medicine.** Columbia, South Carolina 1987:33-40.
31. Monstrey SM, et *al.*: **Free radical cytotoxicity and hyperbaric oxygen (HBO) therapy.**
32. Moon RE: **Pulmonary pathology as a risk factor.** Hyperbaric Medicine 1992, Columbia, South Carolina.
33. Murphy DG, et *al.*: **Tension pneumothorax associated with hyperbaric oxygen therapy.** American Journal of Emergency Medicine 1991; 9(2):176-179.
34. Myers RAM: **Hyperbaric oxygen committee report.** Bethesda, Maryland 1989.
35. Myers RAM: **The HIV positive patient.** Hyperbaric Medicine 1993, Columbia, South Carolina.
36. Nemiroff PM, et *al.*: **Effects of cis-platinum and hyperbaric oxygen on wound healing in mice.** Annual Scientific Meeting, UHMS 1988; 15 (5.53).
37. Palmquist BM, et *al.*: **Nuclear cataract and myopia during hyperbaric oxygen therapy.** Brit J Ophth 1984; 68:202-207.
38. Rees TD, et *al.*: **The effect of cigarette smoking on skin-flap survival in the face lift patient.** Plastic and Reconstructive Surgery 1984; 73(6):911-915.
39. Reus WF, et *al.*: **Acute effects of tobacco smoking on blood flow in the cutaneous micro-circulation.** Brit J. Plastic Surgery 1984; 37:213-215.
40. Ricci B, Cologero G: **Oxygen induced retinopathy in newborn rats: Effects of prolonged normobaric and hyperbaric oxygen supplementation.** Pediatrics 1984; 76:339-344.
41. Silverman: **Retinopathy of prematurity: Oxygen dogma challenged.** Archives of Disease in Childhood 1982; 57:731-733.
42. Suit HD: **Effect of daily exposure to high pressure oxygen on tumor growth.** American Journal Roentgenol 1966; 97:1019-1022.
43. Telford IR, et *al.*: **Hyperbaric oxygen causes fetal wastage in rats.** Lancet 1969; 2:220-221.
44. Thombs P: **The pregnant patient referral.** Hyperbaric Medicine 1993, Columbia, South Carolina.
45. Thombs P: **Pregnancy as a risk factor.** Hyperbaric Medicine 1993, Columbia, South Carolina.
46. Upton PG, et *al.*: **Effects of antioxidants and hyperbaric oxygen in ameliorating experimental doxorubicin skin toxicity in the rat.** Cancer Treatment Reports 1986; 70(4):503-507.
47. VanHoesen KB, et *al.*: **Should hyperbaric oxygen be used to treat the pregnant patient for acute carbon monoxide poisoning?** JAMA 1989; 261:1039-1043.
48. Vazquez RL, Spahr RC: **Hyperbaric oxygen use in neonates.** AJDC 1990; 144:1022-1024.
49. Walsh JM: **The effects of drugs in the underwater environment.** San Antonio, Medical Seminars, Inc. 1981.
50. Weiss LD, Van Meter KW. **The applications of hyperbaric oxygen therapy in emergency medicine.** American Journal of Emergency Medicine 1992; 10(6):558-568.
51. Williams RB: **Proceedings: 2 5th Annual Meeting Association Academic Surgery 1991 , Colorado Springs, Colorado.**
52. Wirjosemito SA, Touhey JE: **Hyperbaric oxygen therapy and hereditary spherocytosis: Report of 2 cases.** Journal of Hyperbaric Medicine 1988; 3(1):45-50.
53. Wolf HK: **Barotrauma and air embolism in hyperbaric oxygen therapy.** American Journal of Forensic Medicine and Pathology 1990; 11(2):149-153.
54. Zamboni WA: **Necrotizing soft tissue infections.** Hyperbaric Medicine 1993, Columbia, South Carolina.