

Chronic Refractory Osteomyelitis

J. Benjamin Jackson III, MD, MBA, FAOA, FACS

Hyperbaric Oxygen Therapy for Chronic Refractory Osteomyelitis

Hyperbaric Medicine Course
Dept. of Orthopedic Surgery/USC
Columbia, SC

J. Benjamin Jackson III, MD
Frank Voss, MD

9/3/2020 1

1


Full Disclosure



9/3/2020 2

2

"Education is not the learning of facts, but the training of the mind to think."
-Albert Einstein



Objectives

- Review Chronic Refractory Osteomyelitis (CRO) and why HBO might help
- Propose a schematic model to help understand CRO
- Review clinical studies
- Propose a limited role for HBO

9/3/2020 3

3

Definitions: Osteomyelitis

- Acute
- Chronic – 6 to 8 weeks
- Refractory – Has failed an attempt at eradication (usually surgical)
- Chronic, refractory case for insurance approval – 6 weeks + eradication att.
- Chronic, refractory case series – usually have persisted 6 months and failed an attempt at eradication

9/3/2020 4

4

Anatomy of Osteomyelitis: Acute vs. Chronic

<ul style="list-style-type: none"> Single abscess Minimal bone reaction Infrequent bacteria beyond abscess Limited hypoxic, hypovascular zone 	<ul style="list-style-type: none"> Multiple abscesses Extensive bony reaction with sequestra and involucrum Frequent bacteria beyond abscess Large hypoxic, hypovascular zone
---	---

9/3/2020 5

5


Chronic osteomyelitis of the distal radius



9/3/2020 6

6

CRO: Nature of the problem

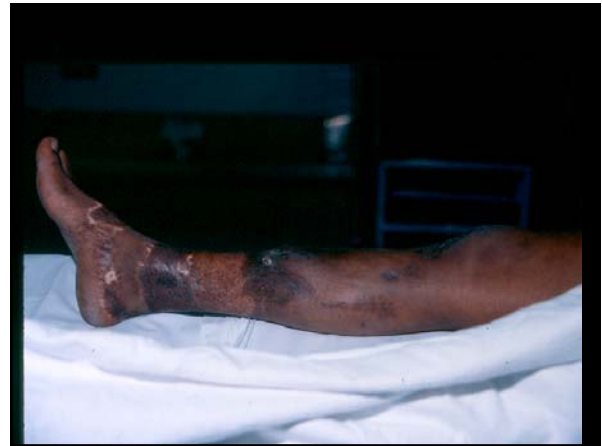

An iceberg floating in the ocean, with only a small portion above water and a much larger portion submerged below. This illustrates the concept of Chronic Refractory Osteomyelitis (CRO) where the visible part is the infection and the larger hidden part is the diseased bone.

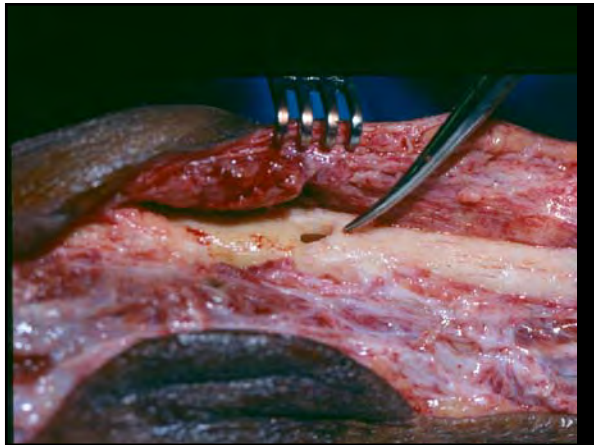
- Cluster of bacteria – aerobes, anaerobes, or microaerophilic
- Diseased, hypovascular and hypoxic bone
- Decreased activity of polymorphonuclear leukocytes, osteoclasts, osteoblasts and fibroblasts

9/3/2020 7

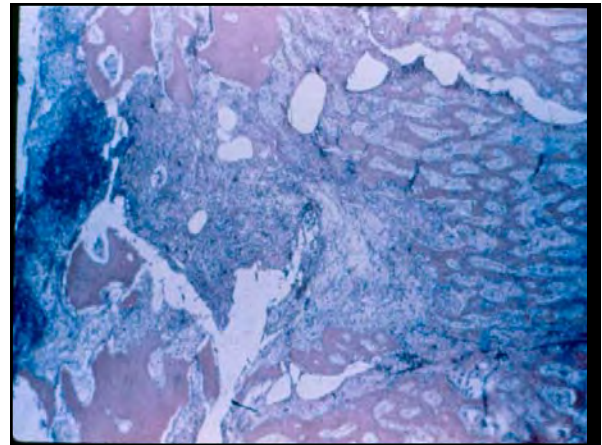
7



8




9



10

HBO to the rescue!



A photograph of a vibrant rainbow arching over a landscape with hills and a cloudy sky, symbolizing hope and recovery.

- Animal studies show that normal bone has a partial pressure of oxygen of about 45mm Hg
- CRO bone = 22 mm Hg
- HBO + CRO = up to 109 mm Hg
- Pulsed therapy – resolves after 15 minutes

9/3/2020 11

11

HBO to the rescue!

- Wakes up the clean up crew – osteoclasts
- Restarts the supply chain – angiogenesis
- Jump starts the repair team – fibroblasts


9/3/2020 12

12

HBO to the rescue!

- Death to the anaerobes!
- Death to the microaerophilic bacteria
- Both lack superoxide dismutase

DOCTORS



9/3/2020 13

13

HBO to the rescue!

- Death to the aerobes!
- HBO revs up the phagocytosis of bacteria by polymorphonuclear leukocytes

9/3/2020 14

14


HBO to the rescue!

- Actually feeds the antibiotics to the bacteria – enhances transport of aminoglycosides across the cell wall

9/3/2020 15

15

Animal Study



Shows synergistic but not “stand alone” treatment capability
Setting is chronic osteomyelitis due to pseudomonas in a rabbit tibia

9/3/2020 16

16

Effects of Tobramycin and Hyperbaric Oxygen on Experimental *Pseudomonas aeruginosa* Osteomyelitis*


	Day 14	Day 21	Day 28	Day 42
Control	5.24±0.19	5.40±0.22	5.59±0.30	6.00±0.19
Hyperbaric oxygen		5.74±0.29	5.13±0.21	5.81±0.31
Tobramycin		4.89±0.34	4.98±0.39	4.27±0.31
Hyperbaric oxygen and Tobramycin		3.92±0.50	3.89±0.32	3.38±0.27

TABLE 2 *The results of the Quantitative *Pseudomonas aeruginosa* tibial counts are expressed as the mean + SEM log base 10. The mean *Pseudomonas aeruginosa* tibial count at the beginning of therapy was 5.24±0.19. Tobramycin was given at 5 mg/kg twice a day before HBO therapy. Hyperbaric oxygen was given twice a day for 95 minutes at 2.5 ATA for all groups, n = 11-12.

9/3/2020 17

17

Tools for understanding clinical studies of CRO



- Classification scheme of Cierny and Mader
- Efficacious modalities
- A new model for CRO
- Insight into the surgical brain

9/3/2020 18

18

Ciorny-Mader Classification

- Anatomic:
 - Stage 1 – Medullary with nidus
 - Stage 2 – Superficial
 - Stage 3 – Localized
well marginated
 - Stage 4 – Diffuse

9/3/2020 19

19

Stage 1: Medullary Osteomyelitis

9/3/2020 20

20

Stage 2: Superficial Osteomyelitis

9/3/2020 21

21

Stage 3: Localized Osteomyelitis

9/3/2020 22

22

Stage 4: Diffuse Osteomyelitis

9/3/2020 23

23

Ciorny-Mader Classification

- Physiologic
 - A Host – Normal
 - B Host - Local Compromise (B1)
Systemic Compromise (Bs)
Local + Systemic (B1s)
 - C Host – Significantly immunocompromised

9/3/2020 24

24

Impaired Hosts Systemic Local



- Malnutrition
- Renal/liver failure
- Chronic hypoxia
- Immune def.
- Malignancy
- DM
- Extremes of age
- Tobacco/EtOH abuse
- Venous stasis
- PVD
- Arteritis
- Scarring
- Radiation fibrosis
- Small vessel disease
- Neuropathy
- Lymphedema

9/3/2020

25

25

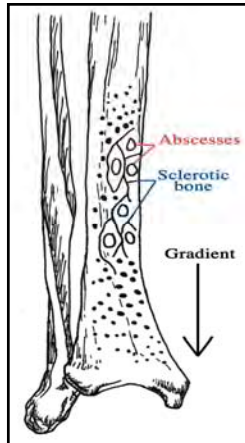
Osteomyelitis: Efficacious Modalities

- Antibiotics – systemic, local
- Surgical debridement
- Improve local blood supply, i.e. flap
- Hyperbaric oxygen (HBO)

9/3/2020

26

26

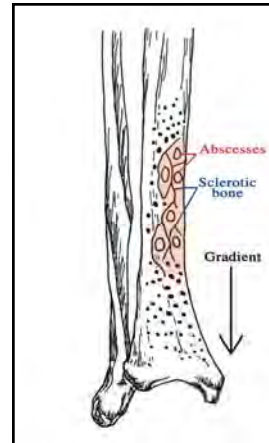


New concept for chronic osteomyelitis:

Gradient of partial pressure of oxygen , blood flow, and bacterial count

27

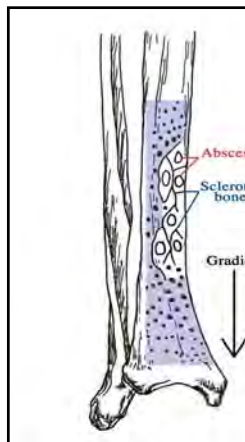
27



Standard surgical debridement ends within the gradient

28

28



Wide surgical excision: less common because of decreased reconstructability

29

29

Debridement

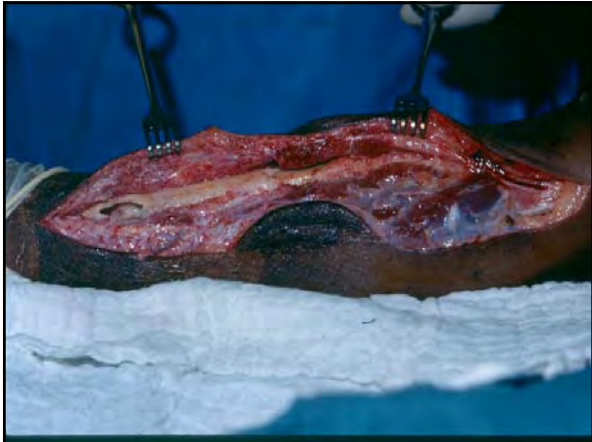- Surgical judgment and limits of reconstructability
- Punctate bleeding, the Paprika sign
- Tetracycline labeling, Wood's lamp
- MRI
- Laser doppler flowmetry



9/3/2020

30

30



31

Laser Doppler Flowmetry

- Duwelius and Schmidt
- Chronic osteomyelitis and infected nonunions
- Readings less than 75mV indicate non-viable bone and risk of recurrent infection

9/3/2020 32

32

Microvascular free flap




- Has enhanced “dead space” management
- Maynor, et al. concluded it was slightly more helpful than HBO with level IV evidence

9/3/2020 33

33

Clinical studies



- Watch out! Nearly all are level 4 evidence
- One busy summary slide
- A few singled out studies

34

34

Clinical Studies in CRO: All with antibiotics, surgery

Name, date	HBO	Flap	Pts	Success	F/U interval
Deppenbusch, 1972	+	-	25	70%	60 mos.
Morrey, 1979	+	-	40	85%	23 mos.
Papineau, 1979	-	-		93%	24 mos.?
Davis, 1984	+	-	38	66%	7-10 yrs.
Arnold, Irons, 1984	-	+	18	76%	18 mos.
Weiland, 1984	-	+	33	79%	41 mos.
Chen, 1997	+	-	15	86%	17 mos.
Maynor, 1998	+	+	34	81%	24 mos.

9/3/2020 35

35

Cierny, Mader, 1987

- Antibiotics, surgery, HBO, some flap
- 118 patients, >24 months
- Stage IIB – 71%
- Stage IIIB – 100%
- Stage IVB – 86%
- Level IV (case series, historical controls)

9/3/2020 36

36

Esterhai, 1988

- Antibiotics, surgery, HBO, no flap
- 14 patients in each group
- Matched comparison study
- HBO did not increase efficacy
- Critique: inadequate surgery common
- Level III (case controlled study, retrospective, matched)

9/3/2020

37

37

Simpson, 2001

- Antibiotics, 3 surgical groups, rare flap, no HBO, antibiotic beads
- 50 patients
- Wide excision – 100% at 2 yrs
- Marginal excision – 72% at 2 yrs
- Intralesional excision – 0% at 2 yrs
- Level II (nonrandomized prospective cohort study)

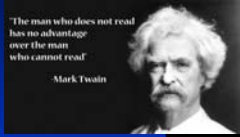
9/3/2020

38

38

Cierny, 1999

“Despite recent advances in medical science, the quality of surgical debridement remains the most critical factor in the successful management of chronic orthopedic infections.”



9/3/2020

39

39

Why isn't everyone using HBO?

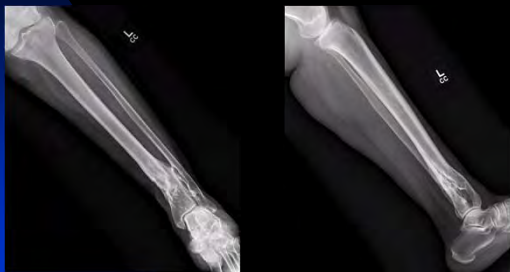- Bone transport
- Free flaps
- Local antibiotic delivery
- Holy grail – bone producing paste

9/3/2020

40

40

Bone transport




9/3/2020

41

41

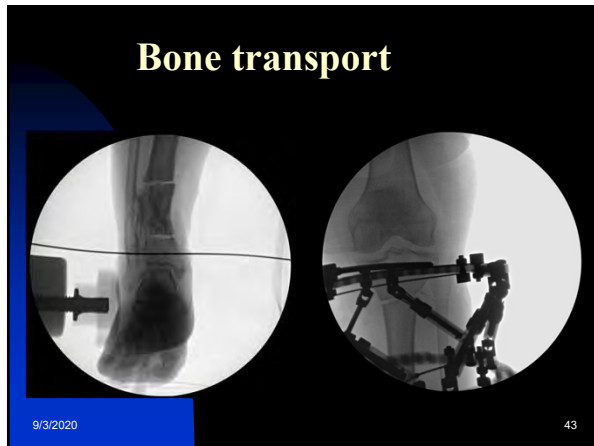
Bone transport



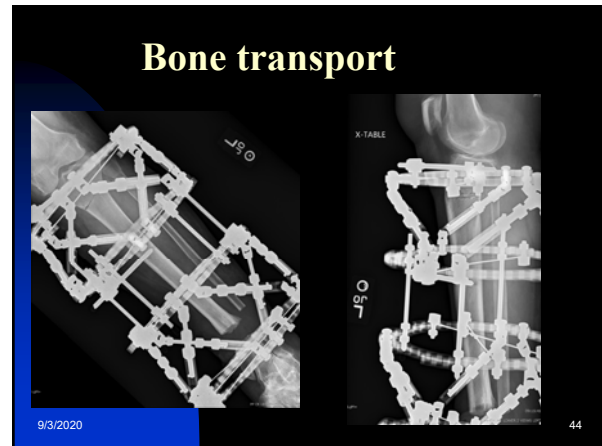
9/3/2020

42

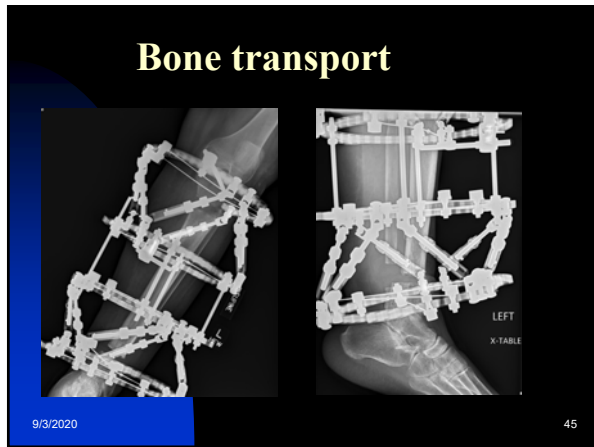
42



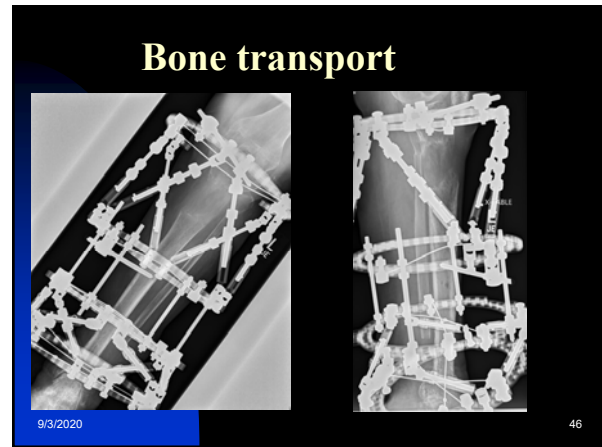
43



44



45



46

Future study

- Extent of debridement guided by MRI or a different “probe”
- Animal studies within the gradient: (i.e. 65-80mV on the laser doppler flowmetry) with and without HBO, with and without a flap, with and without antibiotic beads

9/3/2020 47

47

Conclusions: HBO for CRO

- Animal models have shown modes and efficacy of HBO
- Human studies hint at good efficacy (level IV) but are limited by an ill-defined debridement
- Debride widely, i.e. use a saw
- Use a “probe”
- HBO is an adjunctive modality only
- HBO is indicated when the debridement ends in “the gradient” and in the compromised host

9/3/2020 48

48

HYPERBARIC OXYGEN AND OSTEOMYELITIS

*Department of Orthopaedic Surgery
University of South Carolina School of Medicine
Columbia, South Carolina*

I. Bone Anatomy

- Diaphysis
- Metaphysis
- Epiphysis
- Cortex
- Cancellous or medullary bone
- Periosteum
- Nutrient artery

II. Osteomyelitis

- Osteo -- bone
- Myleos -- marrow
- Itis -- inflammation
- Actual usage -- infection of the bone by bacteria, fungi or mycobacteria

III. Diagnosis of Osteomyelitis

- Acute -- pain, swelling, fever. Radiographic changes may not be seen for several days -- then look for osteolysis, periosteal new bone. Bone scan and aspiration helpful.
- Chronic -- Pain, sometimes drainage or sinus. Radiographs -- sclerosis, lytic areas, sequestrum or involucrum. Biopsy may be required. Specific definition is: bone infection that persists > 6 months, exposed bone, persistent drainage, and a positive culture.

IV. Anatomic Types of Osteomyelitis Cierny and Mader⁽¹⁾

A. Stage I: Medullary

- II: Superficial
- III: Localized
- IV: Diffuse

B. Host A: Normal

B: Systematic Compromise (Bs)

- ~ Malnutrition
- ~ Renal, liver failure
- ~ Alcohol abuse

- ~ Immune Deficiency
- ~ Malignancy
- ~ DM
- ~ Steroid therapy
- ~ Smoking
- ~ Chronic Hypoxia
- ~ Rheumatoid arthritis
- ~ Immunosuppression

Local Compromise (Bl)

- ~ Chronic lymphedema
- ~ Venous Stasis
- ~ Major Vessel Compromise
- ~ Arteritis
- ~ Extensive scarring
- ~ Radiation fibrosis
- ~ Small vessel disease
- ~ Complete loss of local sensation

C: Treatment worse than disease

V. RMH Protocol

- Inclusion: Chronic osteomyelitis, positive wound culture, failure after a surgical debridement and appropriate antibiotics
- Rx: 2.0 ATA for 90 minutes, qd or bid, adjunctive whirlpool if indicated
- See printed protocol

VI. Osteomyelitis -- pathology

- Classic hematogenous occurs in metaphysis. Bacterial proliferation -- inflammation -- decreased blood flow -- local hypoxia. Leads to abscess and bone death.
- Chronic has many residual “pockets” of bacteria and significantly decreased blood flow and oxygen to the bone.

VII. Osteomyelitis -- Treatment (classical)

- Surgical debridement of devitalized tissue
- Medical management with antibiotics -- based on sensitivities

VIII. Hyperbaric Oxygen

- First reports of adjunctive use in 1960's^(2,3,4)
- Animal models (Mader)⁽⁵⁾: experimental osteomyelitis in a rabbit model was shown to have a bone oxygen tension in infected tibiae of 23mmHg or less. In the normal tibia, the oxygen tension was 45mmHg. S.Aureus

was less effectively killed by phagocytes at the lower oxygen tension. Increased oxygen tension (109mmHg), as found under HBO conditions, increased phagocytic killing of bacteria.

- Medullary Ox. Tension returned to nl in 15 minutes.

IX. Hyperbaric Oxygen -- how does it help^(6,7)

- Increased oxygen tension is directly lethal to anaerobes and some microaerophilic bacteria -- this is thought to be due to their lack of superoxide dismutase
- Increased oxygen tension seems to fuel the phagocytic ability of polymorphonuclear leukocytes. Studies have shown increased kill of S. Aureus, S. Epidermidis, Ps.Aeruginosa, and E. Coli when comparing hyperbaric and hypoxic situations.

X. Hyperbaric Oxygen -- Clinical Studies

- Morrey (1979)⁽⁸⁾ -- Entry: 6 months osteomyelitis, at least 1 attempt at debridement, course of IV antibiotics. Rx: 40 pts, additional debridement, IV antibiotics, HBO at 2.4 ATA -- 90 minutes daily. Results: 34 (85%) remained disease free.
- Davis -- 89% success⁽⁹⁾
- Perrins, Deppenbusch -- about 70% success^(3,10)

XI. Hyperbaric Oxygen -- A matched pair analysis

- Esterhai, 1987⁽¹¹⁾
- 28 patients with chronic refractory osteomyelitis complicated by persistent segmental bone defect, fracture nonunion, septic arthritis, total joint arthroplasty or major systemic disease
- Rx -- initial debridement, antibiotics, one of each pair received HBO at 2 ATA, repeat debridements as necessary
- Results: HBO -- 11 arrested, 3 failures, 2 recurrences; Control - 13 arrested, 1 failure, 1 recurrence

XII. Hyperbaric Oxygen Esterhai

- Discussion -- They felt that seven of the 28 had less than a complete surgical eradication of infection
- Not randomized
- Proposed a national osteomyelitis treatment study group

XIII. Osteomyelitis -- What's New?

- Bone transport
- Free flaps
- Local antibiotic delivery

XIV. Summary

- Scientific basis of HBO use in osteomyelitis seems sound
- HBO is adjunctive in the treatment of osteomyelitis
- Randomized clinical studies are extremely difficult to execute -- none to date

References

1. Cierny G, Mader JT, Penninck J J: **A clinical staging system for adult osteomyelitis.** Contemporary Orthopedics 1985;10(5):17-37
2. Slack WK, Thomas DA, Perrins D: **Hyperbaric oxygenation in chronic osteomyelitis.** The Lancet 1965;1093-1094
3. Perrins DJ, Maudsley RH, Colwill RR, et al.: **OHP in the management of chronic osteomyelitis. In: Brown IW, Cox BG.** Eds. Proceedings of the third international conference on hyperbaric medicine, publ. 1404. Washington, DC: National Academy of Sciences, 1966:578-584
4. Goulon M, Rapin M, Letournel E, et al.: **Five cases of suppurated pseudoarthrosis (osteomyelitis) treated by hyperbaric oxygenation. In: Brown IW, Cox BG.** Eds. Proceedings of the third international conference on hyperbaric medicine, publ. 1404. Washington, DC: National Academy of Sciences, 1966:585-591
5. Mader J, Brown GL, Gucklan JC: **A mechanism for the amelioration by hyperbaric oxygen of experimental staphylococcal osteomyelitis in rabbits.** The Journal of Infectious Diseases 1980;142(6):915-922
6. Mader JT: **Bacterial osteomyelitis.** Hyperbaric Oxygen Therapy: A Critical Review, Undersea and Hyperbaric Medical Society 1991;75-94
7. Davis JC: **Refractory osteomyelitis.** Problem Wounds, The Role of Oxygen 1988; Chpt. 5, Elsevier Science Publ. Co., New York
8. Morrey BF, Dunn JM, Heimback RD, et al.: **Hyperbaric oxygen and chronic osteomyelitis.** Clinical Orthopaedics and Related Research 1979;144:121-127
9. Davis JC, Heckman JD, Delee JC, et al.: **Chronic non-hematogenous osteomyelitis treated with adjuvant hyperbaric oxygen.** The Journal of Bone and Joint Surgery 1986;68-A:1210-1217
10. Deppenbusch FL, Thompson RE, Hart GB: **Use of hyperbaric oxygen in the treatment of refractory osteomyelitis: a preliminary report.** J. Trauma 1972;12:807-812
11. Esterhai J, Pisarello J, Brighton CT, et al.: **Adjunctive hyperbaric oxygen therapy in the treatment of chronic refractory osteomyelitis.** The Journal of Trauma 1987;27(7):763-768

Suggested Reading

Calhoun JH, Cobos JA, Mader JT: **Does hyperbaric oxygen have a place in the treatment of osteomyelitis?** Orthopedic Clinics of North America 1991;22(3):467-471